

HEAD AND NECK

- [Development of the Head and Neck](#)
 - [Cranial Nerves](#)
 - [The Face](#)
 - [Spinal Cord and Suboccipital Region](#)
 - [Scalp and Cranial Fossa](#)
 - [Eye and Orbit](#)
 - [Triangles of the Neck](#)
 - [Nose and Paranasal Sinuses](#)
 - [The Mouth](#)
 - [The Pharynx](#)
 - [The Larynx](#)
 - [The Ear](#)
 - [Lymphatics](#)
-

DEVELOPMENT OF THE HEAD AND NECK

NEUROCRANIUM: The part of the skull that surrounds the brain.

- CARTILAGINOUS NEUROCRANIUM (CHONDROCRANIUM): Neurocranium that develops by endochondral ossification (with a cartilaginous intermediate)
- MEMBRANOUS NEUROCRANIUM: That part of the skull that develops by membranous ossification.
 - The **Frontal and Parietal bones** are membranous.
 - **Sutures** are connections between bones. They *allow for growth of the cranium*.
 - **Fontanelles** occur at the intersection of two sutures.
 - There are six of them.
 - The **Anterior Fontanelle** stays open until the middle of the 2nd year. KNOW THAT!
 - **Craniostenosis** is the failure for the skull to expand due to malformed sutures.

VISCEROCRANIUM: The rest of the skull, not overlying the brain. The Maxilla, Mandible, and facial skeleton.

- ENDOCHONDRAL VISCEROCRANIUM:
 - The middle ear bones are endochondral.
 - Styloid Process of Temporalis
 - Greater Cornu and Inferior body of the Hyoid
 - Laryngeal Cartilages
- MEMBRANOUS VISCEROCRANIUM: Maxillary and Mandibular Prominences

SPECIAL VISCERAL EFFERENT (SVE) FIBERS:

- They all innervate *Branchial Muscles*, derived from **Branchial arches**
- They all originate from the **Nucleus Ambiguus**.

GENERAL EFFERENT (GSE, GVE) FIBERS: They innervate muscles that are derived from **somites**.

BRANCHIAL (PHARYNGEAL) ARCHES: They are primitive gills in the neck region of the embryo.

- In humans, we form a primitive gill but then we don't break down the membranes to form mature gills.
- This is an example of ontogeny recapitulating phylogeny, and so is the Mesonephric Duct of the Kidney, which develops and then disintegrates, being replaced by metanephric duct.
- Two different types of mesenchyme compose the Neural Arches:
 - **Neural Crest:** Forms the **Arch Cartilages**. The arch cartilages are made of neural crest! So this would be *ectodermal (neural crest) mesenchyme*.
 - **Mesodermal:** The rest of the neural arch is mesodermal mesenchyme.

BRANCHIAL POUCHES: The outpocketing of endoderm, or the endodermal component on the inside of each arch.

BRANCHIAL CLEFTS (GROOVES): The ectodermal ingrowths, found in between each set of arches.

- All of the clefts disappear except the **1st Branchial Cleft, which becomes the External Auditory Meatus**, and the outer epithelium of the tympanic membrane.

ARCH	POUCH	CARTILAGE	MUSCLE	NERVE
Arch I	Tubotympanic Recess, Eustachian Tube	Meckel's Cartilage -- Malleus and Incus; Sphenomandibular Ligament	Muscles of Mastication	Trigeminal (V), Mandibular Branch
Arch II	Palatine Tonsils	Reichert's Cartilage -- Stapes; Styloid Process; Lesser Cornu and superior part of hyoid bone; Stylohyoid Ligament	Muscles of Facial Expression	Facial (VII)
Arch III	Inferior Parathyroids (superior part) and Thymus (inferior part)	Lower part and greater cornu of hyoid bone	Stylopharyngeus	Glossopharyngeal (IX)
Arches IV - VI	From Pouch IV: Superior Parathyroids (dorsal part) and Ultimobranchial Body (ventral part)	Thyroid Cartilages	Intrinsic muscles of Larynx	Vagus (X)

DEVELOPMENT OF THE MOUTH:

- The **Breakdown of the Buccopharyngeal Membrane** marks the future mouth. It is very important to the embryo, as it allows for communication of amniotic fluid between the inside (gut) of the embryo and the environment.

DEVELOPMENT OF PARATHYROID: Reiterated from above. There are four parathyroid glands on the thyroid, two superior and two inferior.

- The two *Inferior Parathyroids* are formed from **Pouch III**. Pouch III forms the inferior ones because it also forms part of the Thymus which migrates down to the Anterior Mediastinum, hence the third pouch is dragged down a bit with it.
- The two *Superior Parathyroids* are then formed by **Pouch IV**.

DEVELOPMENT OF THE THYROID GLAND: Starts in the floor of the pharynx and then works its way down.

- For a short time it remains connected to the pharynx by a **thyroglossal duct** which disintegrates in the adult, leaving behind the remnant of the **foramen cecum** of the tongue.

DEVELOPMENT OF THE TONGUE:

- All tongue muscles are **somite-derived** -- not branchial arches!
- Anterior 2/3: Formed from lateral **lingual swellings** from **arch 1** mesenchyme.
- Posterior 1/3: From **hypobranchial eminence** from **arch 3** mesenchyme.

DEVELOPMENT OF THE FACE:

- It forms from five processes.
 - **FRONTONASAL PROCESS:** Forms Nasal Processes and Globular Processes

- **PAIRED MAXILLARY PROCESSES:** Grows toward the midline to meet each other.
- **PAIRED MANDIBULAR PROCESSES:** Grows toward the midline to meet each other.
- **Process:**
 - First, **Olfactory Pits** form in the Frontal Process.
 - The Frontal Processes then grow around these pits, forming the following:
 - **2 Lateral Nasal Processes** -- Forms the lateral ala of nose.
 - **1 Medial Nasal Process** -- Forms philtrum.
 - **2 Globular Processes**, on the end of the Lateral Nasal Processes. They fuse together to form the **premaxilla**.
- **CLEFT LIP:** Failure to join of the Maxillary Process and Globular Process. Could be on the same side or bilateral.
 - **Hare Lip:** A midline cleft. Very uncommon.
- **CLEFT PALATE:** *An opening between the nasal and oral cavities, caused by a failure of the **maxillary shelves** to come together and fuse.*
 - This is a different etiology than cleft lip! Although they commonly occur together.

BRANCHIAL FISTULA: Failure of the Branchial clefts to disappear. The cleft stays completely open. They are located on the *side of the neck*.

BRANCHIAL SINUS: Incomplete breakdown of the branchial clefts. The cleft is partially open, either to the inside or outside. They are located on the *side of the neck*.

FIRST ARCH SYNDROMES: Rare syndromes involving the first arch. Due to middle ear ossicles, these syndromes lead to deafness.

GENERAL ARRANGEMENT OF THE CRANIAL NERVES

MOTOR INNERVATION: The *cell bodies for the motor fibers of all cranial nerves are located in the respective **brainstem nuclei** (lower motor neurons)*.

SENSORY INNERVATION: The *cell bodies for the sensory fibers of all cranial nerves are located in the **parasympathetic ganglia** (see below) or **special sensory organs***.

SYMPATHETIC INNERVATION: The sympathetic fibers mostly run along the internal and external carotid arteries to get to their target organs.

1. **SUPERIOR CERVICAL GANGLION:** The highest sympathetic chain ganglia, which contains synapses for all the major sympathetic fibers for the head and neck region.
2. **External Carotid Artery:** Post-Ganglionic sympathetics run along the external carotid to supply the salivary glands and lower face.
3. **Internal Carotid Artery:** Larger portion of sympathetics run along internal carotid, forming the internal carotid plexus.
4. **INTERNAL CAROTID PLEXUS:** In cavernous sinus (probably).
 1. **Deep Petrosal Nerve:** Given off of the internal carotid plexus within the cavernous sinus.
 - From there it goes to Pterygopalatine Fossa and onto nose, palate, and lacrimal glands.
 2. **Sympathetic Root of Ciliary Ganglion:** The internal carotid plexus also sends a sympathetic branch to the Ciliary Ganglion, where it then goes on to form the **Long Ciliary Nerve**, which will innervate the dilator pupillae muscle of the eye.

PARASYMPATHETIC INNERVATION: All Parasympathetic motor innervation to the head synapses exactly once, in one of the four cranial ganglia listed below. All of these ganglia are distributed along branches of the **Trigeminal Nerve (V)**.

1. **CILIARY GANGLION:** Carries parasympathetics from Oculomotor Nerve (III)
 - Located in the posterior of the orbit.
 - GVE (Parasympathetic) innervation is to:
 1. Ciliary Muscles (for Accommodation)

- 2. Sphincter of the Pupil (constriction, or *miosis*).
 - It hangs off of the *Ophthalmic Branch of the Trigeminal Nerve (V¹)*
2. **PTERYGOPALATINE GANGLION:** Carries parasympathetics from Facial Nerve (VII)
 - Located in the Pterygopalatine Fossa in the posterior part of sphenoid bone.
 - GVE (Parasympathetic) innervation is to:
 1. Nose
 2. Palate
 3. Lacrimal Glands
 - It hangs off of the *Maxillary Branch of the Trigeminal Nerve (V²)*.
 3. **SUBMANDIBULAR GANGLION:** Carries parasympathetics from Facial Nerve (VII)
 - Located below and lateral to the tongue.
 - GVE (Parasympathetic) innervation is to:
 1. Submandibular Gland
 2. Sublingual Gland
 - It hangs off of the *Mandibular Branch of the Trigeminal Nerve (V³)*.
 4. **OTIC GANGLION:** Carries parasympathetics from Glossopharyngeal Nerve (IX)
 - Located in Intra-temporal Fossa, just below Foramen Ovale.
 - GVE (Parasympathetic) innervation is to the Parotid Salivary Gland.
 - It hangs off of the *Mandibular Branch of the Trigeminal Nerve (V³)*
 5. **VAGUS NERVE (CN X)**
 - There is no parasympathetic ganglion in the head for the vagus nerve.
 - Sends parasympathetic innervation to the thoracic and abdominal viscera.
-

CRANIAL NERVE I: OLFACTORY NERVE

OLFACTORY MUCOSA: There are actually multiple olfactory nerves in the olfactory mucosa of the superior part of the nasal cavity. They pierce the **Cribriform Plate** of the Ethmoid Bone and lead to OLFACTORY TRACTS on the other side.

SKULL FRACTURES: Can shear olfactory nerves at the cribriform plate, impairing sense of smell. The damage can be unilateral.

TESTING THE NERVE: Wave peppermint under the nostril, testing each nostril separately.

CRANIAL NERVE II: OPTIC NERVE

OPTIC CHIASM: The convergence of the two optic nerves.

1. It occurs at the *sella turcica*, on the body of the sphenoid bone, right at the *Pituitary Gland*.
2. *Fibers from the medial side of each eye cross at the Optic Chiasm, to join the Optic Tract on the opposite side.*
 - So *medial fibers* from the Left Eye will go to the right side of the brain, and *medial fibers* from the right eye will go to the left side of the brain.
 - These fibers are carrying *peripheral visual information* for both respective eyes.

3. *Fibers from the lateral side of each eye do not cross at the Optic Chiasm, but instead join the Optic Tract directly on their own side.*
4. **TUNNEL VISION:** *Indicates a lesion at the optic chiasm. Medial fibers have been impinged upon, destroying peripheral vision in both eyes.*
 - **Pituitary Tumor** can impinge on the optic chiasm, causing tunnel vision.

OPTIC TRACT: That portion extending between the Optic Chiasm and the **Lateral Geniculate Nucleus** in the brainstem. This portion of nerve is not properly called the Optic Nerve.

CRANIAL NERVE III: OCULOMOTOR NERVE

SUPERIOR DIVISION: Somatic innervation to the superior rectus and levator palpebrae muscles.

INFERIOR DIVISION: Somatic innervation to the medial and inferior rectus muscles.

- The inferior division also carries Parasympathetic Fibers, via the **Short Ciliary Nerve**, to the Sphincter Pupillae and Ciliary Muscles (constrict eye and accommodate for near vision).

UNILATERAL LESION OF OCULOMOTOR NERVE: Damage would be as follows.

1. "Lateral Strabismus" = *The eyeball will point downward and outward.*
 - Unchecked tension of the Lateral Rectus (CN VI) will abduct it (pull it outward)
 - Unchecked tension of the Superior Oblique (CN IV) will pull the eye *down and outward* -- not upward!
2. "Ptosis" = *The eyelid will droop.*
 - This is due to lost innervation of the Levator Palpebrae muscle.
 - There may be tonic tension of the *Frontalis Muscle* as well, in order to compensate for drooping eyelid.
3. "Mydriasis" = *The pupil will be dilated.*
 - Due to lost innervation of the Sphincter Pupillae.
4. *Accommodation of the lens will be lost.*
 - Due to lost innervation to Ciliary Muscle.

CRANIAL NERVE IV: TROCHLEAR NERVE

PATHWAY IN BRAIN:

- It is the only cranial nerve that originates from the opposite of the brain.
- It is the only cranial nerve that exits from the dorsal side of the cranium, so it has a very long path.
- It is the only cranial nerve associated with the eye, that doesn't enter the orbit through a tendinous ring.

CAVERNOUS SINUS: It runs in the cavernous sinus. If there is ever brain hemorrhage, pressure from excess CSF can damage the Abducens nerve.

INJURY: Injury to the Trochlear Nerve or Superior Oblique Muscle will cause someone to tilt their head slightly in compensation.

CRANIAL NERVE V: TRIGEMINAL NERVE

TRIGEMINAL GANGLION: It contains the *sensory* cell bodies for the Trigeminal Nerve. *It contains no synapses.*

- The *Motor* cell bodies are in the **Masticator Nucleus** within the pons.

V¹ -- OPHTHALMIC NERVE -- Purely Sensory Nerve.

- It runs through the *lateral wall of the Cavernous Sinus*.
- It exits through **Superior Orbital Fissure** to enter the orbit.
- Associated Ganglion: **CILIARY GANGLION**. It carries *parasympathetic motor fibers* from the **Oculomotor Nerve (CN III)**, which go on to innervate extrinsic eye muscles.

V² -- MAXILLARY NERVE -- Purely Sensory Nerve.

- It runs through the *lateral wall of the cavernous sinus*.
- It exits through **Foramen Rotundum**, in the Greater Wing of the Sphenoid.
- Associated Ganglion: **PTERYGOPALATINE GANGLION**. It carries *parasympathetic motor fibers* from the **Facial Nerve (CN VII)**, which goes on to innervate muscles of facial expression.

V³ -- MANDIBULAR NERVE-- Mixed nerve. The only branch of the Trigeminal to carry any motor innervation.

- It exits through **Foramen Ovale**, in the Greater Wing of the Sphenoid.
- Associated Ganglia:
 - **OTIC GANGLION:** Carries *parasympathetic motor fibers* from the **Glossopharyngeal Nerve (CN IX)**, which go on to innervate the Parotid Salivary Gland.
 - It is located in the **Infratemporal Fossa**
 - **SUBMANDIBULAR GANGLION:** Carries *parasympathetic motor fibers* from the **Facial Nerve (CN VII)**, which go onto innervate the Submandibular and Sublingual glands.
- Motor Innervation: Muscles of mastication; Anterior belly of digastric and mylohyoid; Tensor tympani and tensor veli palati.
- Sensory Innervation: It sends up a **meningeal branch** to innervate part of the meninges.

TIC DOULOUREUX: A severe split second pain in the cutaneous region of the Trigeminal nerve.

- Pains runs through Mandibular and Maxillary divisions, i.e. region around mouth.

MENINGEAL BRANCHES: All branches of Trigeminal send some meningeal branches to the meninges of the brain. If something is irritating the meninges, the pain information will be sent back through the Trigeminal.

- In all cases, meningeal branch will be given off before each branch exits its respective foramen.

CRANIAL NERVE VI: ABDUCENS NERVE

CAVERNOUS SINUS: It runs in the cavernous sinus. If there is ever brain hemorrhage, pressure from excess CSF can damage the Abducens nerve.

STRABISMUS: The inability to direct both eyes toward the same object.

INJURY TO ABDUCENS: The eye on the affected side *rotates inward (adducts)*, due to the unopposed action of the medial rectus muscle.

CRANIAL NERVE VII: FACIAL NERVE

Three Main Functions:

- Innervate the Muscles of Facial Expression
- Supply special sense of taste to anterior 2/3 of tongue, via Chorda Tympani Nerve.
- To innervate all facial glands (salivary, nasal, lacrimal), EXCEPT the Parotid.
- There is also a small area of somatic sensation carried by the facial nerve, around the ear canal ear drum.

The **GENICULATE GANGLION** houses the cell bodies for all fibers of the Facial Nerve. It *has no synapses*.

PATHWAYS OF THE FACIAL NERVE: All fibers of the facial nerve exit the cranium at the **INTERNAL ACOUSTIC MEATUS** in the middle ear. From there, all fibers (except sensory to the ear) go to the GENICULATE GANGLION. From there, the nerve splits into two parts: a special-efferent motor division (to innervate facial-expression muscles) and a parasympathetic motor division (to innervate glands)

1. Motor Fibers of Facial Expression (SVE): They all bend downward and all head out the **Stylomastoid Foramen** and then pass through the **Parotid Gland** (but they do not innervate it). Then they divide into five branches.
 - All of these muscles are derived from the **second branchial arch**.
 - TO ZANZIBAR BY MOTOR CAR:
 1. **TEMPORAL BRANCH** -- Frontal Muscles
 2. **ZYGOMATIC BRANCH** -- Orbicularis Oculi
 3. **BUCCAL BRANCH** -- Buccinator, Orbicularis Oris, Zygomaticus
 4. **MANDIBULAR BRANCH** -- Orbicularis Oris, Depressor Labii Inferiores
 5. **CERVICAL BRANCH** -- Platysma
2. Parasympathetic Secretomotor Fibers (GVE): They split into the *Chorda Tympani* and *Greater Petrosal* nerves, and head in two different directions.
 1. **PATHWAY OF CHORDA TYMPANI**: Through Middle Ear -----> Out the **Petrotymppanic Fissure** -----> Joins up with the **Lingual Nerve** -----> **Submandibular Ganglion**, where it synapses -----> Sublingual and Submandibular Salivary Glands
 - So ultimate innervation is **secretomotor innervation** to Submandibular and Sublingual glands.
 2. **PATHWAY OF GREATER PETROSAL**: Middle Ear -----> Out the **Greater Petrosal Hiatus** -----> *back in through the foramen lacerum* -----> Join with sympathetics from Deep Petrosal Nerve to form the *Nerve of Pterygoid Canal* -----> **Pterygopalatine Ganglion**, where it synapses -----> Nasal mucosa and Lacrimal Glands.
 - So, ultimate innervation is **secretomotor innervation** to lacrimal glands and nasal mucosa.

BELL'S PALSY: "Paralysis of the Facial Nerve for no obvious reason." Or, loss of SVE motor innervation of the Facial Nerve.

1. Commonly occurs if the nerve gets impeded or inflamed at the **Stylomastoid Foramen**.
 - Facial paralysis results on the side affected. Patients will be unable to close eyelids, they will droop, and they will have a contorted face due to unopposed muscles on other side.
2. An injury here would *not affect parasympathetic secretomotor innervation* (those are given off before the stylomastoid foramen) -- it would only affect muscles of facial expression.
3. Loss of buccinator muscle can lead to difficulty eating.
4. Inability to close eyelid results in damage to cornea due to dryness of the eye, due to no innervation of palpebral part of orbicularis oculi.

CRANIAL NERVE VIII: VESTIBULOCOCHLEAR NERVE

VESTIBULAR NERVE: Innervates the semicircular canals, utricle, and saccule, and is responsible for dynamic and static balance.

COCHLEAR NERVE: Innervates the cochlea and is responsible for hearing.

INTERNAL ACOUSTIC MEATUS: Cranial Nerve VIII exits out the internal acoustic meatus, along with the Facial Nerve.

ACOUSTIC NEUROMAS: A **neuroma** from a Schwann Cell in the Vestibulocochlear may impinge upon the Vestibular and Cochlear nerves in the Internal Acoustic Meatus. If it is large enough, it may impinge on the Facial Nerve, too.

CRANIAL NERVE IX: GLOSSOPHARYNGEAL NERVE

Five Functions of Glossopharyngeal Nerve:

- Innervates Stylopharyngeus Muscle.
- Special sense of taste to posterior 1/3 of tongue
- General sensation to posterior 1/3 of tongue, lateral oropharyngeal wall, part of soft palate
- Parasympathetic secretomotor to Parotid Gland
- Visceral Sensation from the *Baroreceptors* ("blood-pressure" receptors) at the **Carotid Body (Sinus)**, at the bifurcation of the Carotids.
 - These guys carry special chemoreceptors and stretch receptors. They provide feedback to the heart to control heart rate and modulate blood pressure.

TYMPANIC NERVE: Is given off at the Jugular Foramen from the Glossopharyngeal. It carries Parasympathetic innervation to the Parotid, via the Lesser Petrosal.

- It travels through the middle ear (inside the cranium), where it forms the **Tympanic Plexus**.
- It exits the cranium at the **Lesser Petrosal Hiatus** of the Temporal bone.
- After it exits back out, it is known as the Lesser Petrosal Nerve.
- **Lesser Petrosal Nerve:** The continuation of the Tympanic; it synapses at the **Otic Ganglion** and then continues to carry parasympathetic innervation to the Parotid Gland.

GAG REFLEX: Glossopharyngeal can be tested by eliciting a gag reflex. Touch the posterior 1/3 of tongue or palate region to elicit response.

- One should also be able to see *symmetric raising of the soft palate* during swallowing to verify functionality of the nerve.

OVERALL PATH OF GLOSSOPHARYNGEUS TO PHARYNX:

- Through JUGULAR FORAMEN
- Down posterior wall of pharynx to innervate the stylopharyngeus muscle
- Penetrate gap between Superior and Middle Pharyngeal Constrictors, adhered to the Stylopharyngeus muscle.
- Finally, innervation to the posterior 1/3 of tongue.

CRANIAL NERVE X: VAGUS NERVE

Type of Innervation:

1. BRANCHIAL MOTOR (SVE): *All muscles of the larynx, pharynx, and palate, EXCEPT the Stylopharyngeus (IX) and Tensor Palati (V3).*

- In this role, the Vagus is "stealing" some of the innervation from the Spinal Accessory (XI). Hence in this case the Vagus is actually innervating striated rather than smooth muscle.
2. VISCERAL MOTOR (GVE): Parasympathetics to the Thoracic and Abdominal viscera.
 - The Vagus serves no Parasympathetic function in the head and neck region -- only the thorax and abdomen.
 3. VISCERAL SENSORY (GVA): Sensory info from tongue, pharynx and larynx, heart and lungs, CAROTID SINUS (along with CN IX), stomach and intestine.
 4. GENERAL SENSORY (GSA): General sensory from larynx, pharynx, and a small portion of the outer ear and tympanic membrane.
 - General Sensory innervation may include the eardrum itself. These individuals may elicit a gag reflex when cleaning their ears -- due to sensory response from the Vagus!
 5. SPECIAL SENSORY (SVA): Maybe a few taste buds carry taste information via the Vagus.

TACHYCARDIA: To treat a racing heart rate, you can give the patient a **Carotid Body Massage**, at the bifurcation of the Carotids, in attempt to stimulate the visceral sensory components of the Vagus and Glossopharyngeal, to try to slow heart rate by increasing the Vagal stimulation of the heart.

UNILATERAL LESIONS OF THE VAGUS: Lesions of the vagus lead to the following symptoms.

1. *Hoarseness*, due to lost laryngeal function on the affected side.
2. *Difficulty Swallowing*, due to inability to elevate the soft palate on the affected side. This also makes the soft palate *droop on that side*.
3. The *uvula tends to deviate toward the unaffected (intact) side*, due to droop of the soft palate on the affected side.
 - If the uvula deviates toward the left, then damage is to the right Vagus nerve.

SUPERIOR VAGUS GANGLION: It is within the Jugular Foramen. It houses *somatic sensory cell bodies* of the Vagus nerve.

INFERIOR VAGUS GANGLION: It is right beneath the Jugular Foramen, right outside the skull. It houses *visceral sensory cell bodies* for the Vagus nerve.

CRANIAL NERVE XI: SPINAL ACCESSORY NERVE

Two Roots:

1. **Spinal Root:** Gives SVE (Branchial) innervation to *Sternocleidomastoid* and *Trapezius* muscles.
2. **Cervical Root:** Quickly joins up with Vagus (and could be considered part of Vagus) to form the Recurrent Laryngeal Nerve.

NERVE GRAFTS: The function of Spinal Accessory is somewhat redundant.

- It can be used to replace innervation lost by other muscles. The nerve can be redirected to the muscles of facial expression, e.g., and patients can learn to use the new pathway with physical therapy.

DAMAGE TO SPINAL ACCESSORY:

- *Shoulder Droop*, due to lost innervation to upper part of Trapezius.
- Difficulty in turning head, due to lost innervation to Sternocleidomastoid -- but other muscles serve this function as well!

MOTOR CELL BODIES: Lie in the *spinal chord* (C1-C5).

- Fibers run *up* the spinal chord and *into* the cranium through the **Foramen Magnum**, and then back *out* the posterior cranial fossa through the **Jugular Foramen**.

CRANIAL NERVE XII: HYPOGLOSSAL NERVE

INNERVATION: All intrinsic and extrinsic musculature of the tongue, EXCEPT the Palatoglossus which is innervated by the Vagus.

PATH: It exits the posterior cranial fossa through the **Hypoglossal Canal**, which is anterior to the Occipital Condyles.

- It may pass through the Carotid Sheath or on either side of it.
- It passes toward the tongue medial to the posterior belly of the Digastric muscle.
- Upper portions of the Ansa Cervicales will hang off the Hypoglossal in order to reach the strap muscles, but the fibers do not intermix.

DAMAGE TO HYPOGLOSSAL:

1. It would be difficult to stick tongue out.
2. The tongue would *deviate toward the nonfunctional side*, due to functional muscles protruding it in that direction.
 - If tongue deviates to the left, then damage is to the left hypoglossal nerve.

THE FACE

SECOND BRANCHIAL ARCH: All muscles of facial expression are derived from the second branchial arch and are innervated by branches of the Facial Nerve (VII).

Fractures that affect the facial skeleton:

1. **La Fort 1:** A horizontal fracture through the maxilla, at the base of alveolar process (i.e. at the top of the upper teeth).
 - The alveolar process of the maxilla and upper teeth come off as a unit.
 - The rest of the maxilla remains attached to the zygomatic bone.
2. **La Fort 2:** Complete separation of the maxilla. Essentially, the nose is separated from the facial skeleton.
 - Zygomatic bone remains intact and separated from Maxilla.
3. **La Fort 3:** Zygomatic bone separates from the frontal bone. Essentially, the entire face breaks loose from the cranium.
 - The orbits drop down, causing **double vision**.

FACE LACERATIONS: Because facial skin is loose, lacerations in the face tend to gape. Injuries in the face tend to swell more than other tissues.

GALEA APONEUROTICA: Superficial fascia of the scalp. The frontalis muscle inserts into the Galea Aponeurotica.

STARVATION: The **Buccal Fat Pad**, directly *deep to* the Buccinator Muscle, and the **Retro orbital Fat Pad** are the last fat-stores to be used when energy is needed. Thus depletion of these fat-pads (sunken eyes and hollowed out cheeks) indicates starvation.

THE FACIAL ARTERY supplies blood to the superficial structures of face.

1. The facial artery is one of the principle branches given off the *External Carotid*.
2. **PATHWAY** of Facial Artery:
 1. It is given off just deep to the angle of the mandible.
 2. It crosses the inferior border of the mandible *just anterior to the masseter muscle*.
 3. Once its on the anterior surface of the face, it goes up the cheek, past the angle of the mouth, and heads toward the *inner canthus* (medial corner) of the eye.
3. A **Facial Artery Pulse** can be palpated as the artery crosses the mandible just anterior to the masseter muscle.
4. **BRANCHES** of the Facial Artery:
 1. **Superior Labial Branch** above mouth
 - Has anastomoses with the Infraorbital Artery
 2. **Inferior Labial Branch** below mouth
 3. **Angular Artery** heads up to the nose
 - Has anastomoses with the Ophthalmic Artery
 4. **Lateral Nasal Branch**

SUPERFICIAL TEMPORAL ARTERY: The terminal branch of the *External Carotid*.

1. Goes straight up the temporal region of the skull.
2. Branches:
 1. **Frontal Branch**
 2. **Parietal Branch**.
 3. **Transverse Facial Artery** crosses Masseter muscle
3. Anesthesiologists use it to take a pulse. It is found just anterior to the ear, superficial to the zygomatic arch.

VEINS OF THE FACE:

1. Venous Channels:
 1. **Facial Vein** provides the major venous drainage -----> **Internal Jugular Vein**.
 - Facial vein is formed *from* the Supraorbital + Supratrochlear Veins -----> Angular Vein (comes down from medial canthus of eye) -----> Facial Vein.
 - Facial vein then joins with the Submental Vein to *lead to* the Internal and External Jugular Veins.
 2. **Retromandibular Vein** is formed by the union of the Superficial Temporal Vein and Maxillary Vein.
 - It then joins with the Posterior Auricular Vein to form the **External Jugular Vein**.
 - It also gives off a branch back to the facial vein -----> Internal Jugular.
2. **ANASTOMOSES WITH CRANIAL FOSSA:** Clinically important collateral circulation with the dural sinuses occurs at two places:
 1. **Deep Facial Vein** is a communication between the Facial Vein and the **Pterygoid Plexus**.
 2. **Superior Ophthalmic Vein** is a communication between the Facial Vein and the **Cavernous Sinus**.
3. **DANGER TRIANGLE OF THE FACE:** A triangle approximately covering the nose and maxilla, and going up to the region between the eyes. *Superficial Veins communicate with dural sinuses in this region*.
 1. The Facial Vein has no valves. Backflow can cause **infection to get into the dural sinuses, through the Deep Facial Vein (via pterygoid plexus) and Superior Ophthalmic Vein (via Cavernous Sinus)**

LYMPHATIC DRAINAGE:

1. **Parotid Nodes:** Superficial and deep set.
 2. **Submandibular Nodes**
 3. **Retroauricular Nodes**
-

THE SPINAL CORD AND SUBOCCIPITAL REGION

PARTS OF THE VERTEBRAL COLUMN:

1. **BODY:** Faces anteriorly. From C2 on down, they become progressively larger.
2. **VERTEBRAL ARCH:** A complete circle formed by two pedicles and two lamina
 - **PEDICLE** is between the body and transverse process
 - **LAMINA** is between the transverse and spinous process
3. **VERTEBRAL FORAMEN** is the hole enclosed by the vertebral arch, containing the spinal chord
4. **INTERVERTEBRAL FORAMEN** is the hole formed *between the pedicles* at each vertebral level.
 - It is composed of the **SUPERIOR VERTEBRAL NOTCH** of the lower level and **INFERIOR VERTEBRAL NOTCH** of the upper level.
5. **SPINOUS PROCESSES** point posteriorly.
 - **Laminectomy** is a resection between the transverse and spinous processes.
6. **TRANSVERSE PROCESSES** point laterally. There are two of them.
7. **Articular Facets:** Shape varies according to location.
 - **INFERIOR ARTICULAR FACETS** are on either side of spinous process, pointing inferiorly and laterally, and articulating with the superior articular facets of the next level down.
 - **SUPERIOR ARTICULAR FACETS** point upward and laterally.

ATLANTO-OCCIPITAL JOINT: Joint between Atlas and Occipital Condyles. It allows for great flexion and extension and almost no rotation.

- The articular facet is horizontal, facilitating flexion and extension.
- It is the **"yes" joint** -- the joint you use when you nod your head.
- It is stabilized by Anterior and Posterior **Atlanto-Occipital Membranes**.

ATLAS: First Cervical Vertebrae.

- Superior Articular Facet articulates with the Occipital Condyles of the Occipital bone.
- It has *no body or spinous process*.
- It has a **vertebral groove** for the vertebral artery, which has already passed through the foramina transversaria.

ATLANTO-AXIAL JOINT: Between Atlas and Axis. It allows for great rotation but almost no flexion and extension.

- Joint is between the Atlas and the dens of the Axis.
- It is the **"no" joint** -- the joint you use when you rotate head from side to side.
- **Cruciform Ligament:** Extends out from atlas and holds the atlas to the dens of the axis.

1. It has Superior, Transverse, and Inferior portions.

- **Alar Ligament:** Hooks the dens process of C2 directly to the Occipital Condyles, and serves to *limit the rotation of the joint*.

AXIS: Second Cervical Vertebrae.

- It has an odontoid process or **dens** sticking up through the Atlas above it, and forming the Atlanto-Axial Joint.

WHIPLASH: Hyperextension of the neck, common in car accidents. Anterior Longitudinal Ligament is stretched or torn.

Features of Each Type of Vertebrae:

- **CERVICAL VERTEBRAE:** 7 vertebral bones, but 8 intervertebral spinal levels.
 - They have **Foramina Transversaria** going through their transverse processes, which allow passage of the paired *Vertebral Arteries* up and down the spinal column.
 - *Good Flexion and Extension:* Their superior articular facets are more *horizontal*. They are shaped to allow good flexion and extension.
 - This again is mobility at the sacrifice of stability.
 - They all have *small spinous processes* EXCEPT C7. The large spinous process (bump in back of neck) at **C7** is called the **Vertebra Prominens**.
 - C7 is the transition with the Lumbar Vertebrae and has many ligaments, and thus has a larger spinous process.
 - *Each intervertebral cervical spinal level is **above** its corresponding vertebrae.*
 - C1 spinal level is above the Atlas, C2 is above the Axis, and so on.
 - **C8** cervical spinal level is above the first Thoracic Vertebrae. There is no eighth cervical vertebrae.
- **THORACIC VERTEBRAE:** 12 Vertebrae and 12 spinal levels.
 - Articular facets are more *vertical*, allowing very little flexion and extension.
 - They have additional articular facets for the ribs. The two costal articulation at the head and neck of ribs are both synovial joints.
 - *Each intervertebral thoracic spinal level is **below** its corresponding vertebrae*
- **LUMBAR VERTEBRAE:** 5 Vertebrae and 5 spinal levels.
 - Bodies are larger, to support more weight.
 - Articular Facets are almost completely *vertical*, to allow a great amount of **flexion and extension** but very little rotation.
 - *Each intervertebral lumbar spinal level is **below** its corresponding vertebrae.*

LIGAMENTS OF THE SPINAL COLUMN:

1. **Anterior Longitudinal Ligament:** Anterior to the vertebral body, straight up and down the entire column.
 - It *limits extension* -- it prevents hyperextension.
2. **Posterior Longitudinal Ligament:** Posterior to the body, within the vertebral arch, straight up and down the entire column.
 - So, this ligament is the anterior border of the vertebral arch -- anterior to the spinal cord itself.
 - It *limits flexion* -- it stretches when you bend forward.
 - Because of the posterior ligament, herniated disks go *laterally* -- not straight anteriorly.
3. **Supraspinous Ligament:** Long, thick ligament running along with posterior borders of the spinous processes.
 - It *limits flexion* -- it stretches when you bend forward.
4. **Interspinous Ligaments:** Short fibers that run between adjacent spinous processes.
 - It *limits flexion* -- it stretches when you bend forward. It is the most important ligament that *prevents hyperflexion*.

5. **Ligamentum Flavum:** Elastic, thick, dense ligament that runs vertically between adjacent lamina along their interior aspects.

- You can see part of it peering through intervertebral levels.

INTERVERTEBRAL DISC: Helps to provide stability to the vertebral column.

1. **Annulus Fibrosus:** Outer part of the disc, fibrous ring.
2. **Nucleus Pulposus:** Central part of the disc.

- It is derived from notochord. It acts as a shock absorber and semifluid ball bearing.

SPINAL TAP:

- To draw a spinal tap, enter just *lateral to the spinous processes*, and penetrate the *ligamentum flavum* and then the dura levels.
- It is taken **between** Lumbar Vertebrae **L3 and L4** or between **L4 and L5**.
- Layers of Penetration to get to the CSF: Skin -----> Subcutaneous Tissue -----> Supraspinous Ligament (tough) -----> Interspinous Ligament -----> Ligamentum Flavum (perhaps tough) -----> Extra Dural Space (fatty) -----> Dura Mater -----> Arachnoid Mater (tough) -----> Subarachnoid Space

CERVICAL ENLARGEMENT: A bulge in the spinal chord due to the extra fibers necessary to supply the Brachial Plexus for the upper limb.

LUMBAR ENLARGEMENT: A similar bulge in spinal chord due to the extra fibers necessary to supply the Lumbar Plexus for the lower limb.

CONUS MEDULLARIS: The end of the spinal chord, **after L1**. There are no more *cell bodies* past this point.

- **CAUDA EQUINA** = The "Horse's Tail," the long axons that run down the vertebral canal and supply the spinal levels past the Conus Medullaris. It is a collection of dorsal and ventral roots.
- This means that Thoracic and Lumbar nerves descend quite a bit before they exit their respective vertebral levels. Cervical nerves come out almost horizontally.
- The Dura Mater layer of the vertebral column ends between S1 and S2.

SPINAL CHORD and SPINAL NERVES:

1. **Grey Matter:** Central butterfly-shaped portion containing cell bodies.
2. **White Matter:** On either side of the Grey-Matter. It is white because it contains myelinated nerve axons.
3. **Neural Horn:** The edges of the grey matter *within the spinal column*. There are two horns: dorsal and ventral.
 - Dorsal Horn: Relays mostly sensory signals, but it does not house the sensory cell bodies.
 - **Ventral Horn:** Houses the majority of the **motor cell bodies**.
4. **Neural Root:** The beginning of each spinal nerve as it exits the spinal column, *while it is still within the vertebra arch*. There are two roots: dorsal and ventral.
 - **Dorsal Root Ganglion:** *The sensory cell bodies are located within the Dorsal Root Ganglion*, which is in the Dorsal Root of the spinal column.
 - If we clip a dorsal root, we lose sensation but retain motor ability.
 - Ventral Root: Contains outgoing motor neurons, but not the cell bodies.
 - If we clip a ventral root, we only lose motor control but retain sensory ability.
5. **Spinal Nerve:** The fusion of the dorsal and ventral roots, right outside the vertebral arch, at each intervertebral level.

6. **SIMPLE REFLEX ARC:** Stimulus -----> Sensory Nerve -----> Dorsal Root Ganglion (no synapse) -----> Dorsal (sensory) Horn, and possible synapse with motor neuron -----> Ventral (motor) Horn -----> Ventral Root -----> Motor Neuron impulse

MENINGES: "Membranes" -- layers of the brain and spinal chord covering. There are three membranous layers, maters, covering the CNS.

1. **Epidural Space:** Space between the dura mater and periosteum of the skull and vertebrae.
 - It contains fat, arteries, and lots of veins -- which can promote metastases.
 - **OB-GYN EPIDURAL:** Anesthetic commonly given for pain during childbirth. Given at the *sacral hiatus*, about 1 to 2 inches above the tip of the coccyx, to numb all the spinal nerves at that level.
 - Epidural Blocks will anesthetize every rootlet that passes distal to the block.
 - In the brain, the Epidural Space is a *potential space*. In the spinal chord, it is a real space.
2. **Dura Mater:** Tough layer lying *free* within the vertebral column. It is continuous with the cranial dura mater.
 - This is continuous with Dura Mater of brain and *Sclera of the eye*.
3. **Subdural Space:** A potential space not present under nonpathological conditions in the brain or spinal chord.
4. **Arachnoid Mater:** Thin, watertight layer, "spider-web-like"
5. **Subarachnoid Space:** Contains the **CerebroSpinal Fluid (CSF)**
 - It also contains **Denticulate Ligaments**, structures that support the spinal column and keep it centered within the meninges.
6. **Pia Mater:** Unicellular layer directly adherent to the spinal chord.

BLOOD SUPPLY TO SPINAL COLUMN:

1. **Vertebral Artery:** Paired arteries that come off the subclavian, travel within the Foramina Transversaria, and travel through the Foramen Magnum into the brain.
2. **Anterior Spinal Artery:** A single artery given off from the vertebral artery at the brain stem. Supplies anterior 2/3 of spinal chord.
3. **Posterior Spinal Artery:** Two paired arteries.
 - Supplies posterior 1/3 of spinal chord.
4. **Radicular Arteries:** Branch off to local arteries at many spinal levels, providing *extensive collateral circulation* to the spinal column.

Internal Vertebral Venous Plexus: *Valveless* venous drainage system, lying *outside of the dura*.

- Drains superiorly into occipital sinus.
- Drains inferiorly into intervertebral veins and the *Azygos Venous System*.
- Some cancers (e.g. Prostate) tend to metastasize to the spinal chord via these venous plexuses.

SUBOCCIPITAL TRIANGLE: Formed by three muscles: Rectus Capitis Major, and Obliquus Capitis Inferior and Superior. It contains the **Vertebral Artery** and **Suboccipital Nerve**, which is the dorsal ramus of C1.

THE SCALP AND CRANIAL FOSSA

SCALP: Cutaneous cranium superficial to the skull. Its layers fit the acronym SCALP:

1. **S**kin
2. **C**onnective tissue -- highly vascular
3. **A**poneurosis -- *Galea Aponeurotica* = dense connective tissue
 - This is continuous with the **Epicranius** muscle from all sides, consisting of *Frontalis* and *Occipitalis* muscles.
4. **L**oose connective tissue, upon which the aponeurosis glides
5. **P**erosteum -- adherent to bony skull

SCALP LESION: The outermost connective tissue is highly vascular, and the loose connective tissue tends to hold cuts open, resulting in profuse bleeding of scalp. It is easily fixed with stitches

DANGER ZONE: If you get past the aponeurosis (i.e. from a cut), then you have hit the danger zone. Bacteria likes to breed in the loose connective tissue beneath the Galea Aponeurotica.

1. **Diploic Veins:** Veins in the cancellous bone of the skull. These are superficial veins. The Emissary Veins flow into them.
2. **EMISSARY VEINS:** Communicate with the diploic veins superficially. *They run through the Loose-Connective Tissue Layer -- the DANGER ZONE.*
 - If an infection gets in this area, it can easily be carried to the Cerebrospinal fluid via the Emissary Veins.
 - The general blood flow of these veins is *outward* -- out of the cranium.

ARTERIAL SUPPLY TO SCALP:

- From the EXTERNAL CAROTID, we have, from anterior to posterior:
 - **Superficial Temporal Artery** anterior to ear
 - **Posterior Auricular Artery** posterior to ear
 - **Occipital Artery** back of neck
- From the INTERNAL CAROTID, we have two branches, which anastomose with the External Carotid via both Facial Artery and Superficial Temporal:
 - **Supratrochlear Artery:** Frontal region medially
 - **Supraorbital Artery:** Frontal region laterally

CRANIAL FOSSA: The cranium is divided into three regions (fossae), according to the cranial lobes that each region houses.

1. **Anterior Cranial Fossa:** Houses frontal lobes.
 - Includes all of Frontal and Ethmoid bones, and the Lesser Wing of the Sphenoid.
2. **Middle Cranial Fossa:** Houses temporal lobes.
 - Includes the Greater Wing of the Sphenoid, Sella Turcica, and the majority of Temporal Bones.
3. **Posterior Cranial Fossa:** House occipital lobes, cerebellum, and medulla
 - Includes the Occipital bone.

DURAL FOLDS: Extensions of Dura Mater that subdivide the cranial cavity and give support to the brain, such as when bungee-jumping.

- **FALX CEREBRI:** Dural fold going sagittally between the cerebral hemispheres.
 - It connects anteriorly to the **Crista Galli** of the Ethmoid Bone and the **Internal Occipital Protuberance** posteriorly.
 - The *Superior Sagittal Sinus* is the superior limit of the Falx Cerebri, within the dura.
 - The *Inferior Sagittal Sinus* is the inferior limit of the Falx Cerebri, within the dura.
- **TENTORIUM CEREBELLI:** Lateral dural fold separating the cerebrum from the cerebellum.
 - The Falx Cerebri holds it down posteriorly, where they intersect.
 - The *Transverse Sinus* runs through it posteriorly.
 - The *Superior Petrosal Sinus* runs through it anteriorly.
 - **INCISURA TENTORIA:** The hole in the Tentorium Cerebelli that allows the cerebrum to communicate with the cerebellum.
- **DIAPHRAGMA SELLAE:** Small donut-shaped dural fold covering the Pituitary Gland, at the *Sella Turcica* of the Sphenoid Bone.

DURAL SINUSES: Venous sinuses which drain all blood from the brain. They are formed within the **dura mater** layer of the meninges. The Dura Mater splits into two layer in the cranium: A Periosteal (outer) Layer and a Meningeal (inner) Layer. **The dural sinuses form between them.**

1. **SUPERIOR SAGITTAL SINUS:** Runs within superior aspect of the Falx Cerebri.
 - **ARACHNOID VILLI:** Granulations from the Arachnoid Mater project into this sinus, providing a way to **empty CerebroSpinal Fluid into the Superior Sagittal Sinus**. This is how we recycle cerebrospinal fluid (CSF).
 - It drains into the CONFLUENCE OF SINUSES -----> TRANSVERSE SINUS
2. **INFERIOR SAGITTAL SINUS:** Runs within the inferior aspect of the Falx Cerebri.
 - It joins the GREAT VEIN OF GALEN to form the Straight Sinus.
 - From there Blood Drainage is as follows: STRAIGHT SINUS -----> TRANSVERSE SINUS
 - The Sigmoid Sinus also communicates with the Internal Vertebral Venous Plexus.
3. **OCCIPITAL SINUS:** Lies in the Falx Cerebellia. It drains blood as follows: OCCIPITAL SINUS -----> CONFLUENCE OF SINUSES -----> TRANSVERSE SINUS
4. **CONFLUENCE OF SINUSES:** The junction between the Superior Sagittal, Straight, and Transverse Sinuses. It leads into the Transverse Sinus. The occipital sinus is caudal to it.
5. **TRANSVERSE SINUS:** It receives blood from all three sinuses above: Superior and Inferior Sagittal, and Occipital. It drains blood as follows:
 - TRANSVERSE SINUS -----> SIGMOID SINUS -----> INTERNAL JUGULAR VEIN
6. **SUPERIOR PETROSAL SINUS:** *Drains the Cavernous Sinus* -----> OCCIPITAL SINUS
7. **INFERIOR PETROSAL SINUS:** *Drains the Cavernous Sinus* -----> INTERNAL JUGULAR VEIN directly.

CAVERNOUS SINUS: VERY IMPORTANT because it contains lots of nerves and vessels running through it.

- It is located at the **Sella Turcica** of the Sphenoid, surrounding the Pituitary Gland, within the **Diaphragma Sella** dural fold.
- It receives blood from:
 - Superior and Inferior Ophthalmic Veins
 - Superficial Middle Cerebral Vein
 - Sphenoparietal Sinus
- It drains blood into:
 - *Inferior and Superior Petrosal Sinuses*.
 - *Pterygoid Plexus*.
- It has the following running through it:

- *All of Cranial Nerves III - VI, except V3*
 - All of the above run, in numerical order, along the *lateral wall of the cavernous sinus* from superior to inferior, EXCEPT for the **Abducens Nerve (VI)** which runs directly through the cavernous sinus.
- **The Internal Carotid Artery.** This is also completely surrounded within the Cavernous Sinus.
- The Sphenoidal Paranasal Sinus, in the sphenoid bone, is inferior and medial to the cavernous dural sinus.
- SPHENOID FRACTURE: A fracture at the base of the sphenoid could produce a bone fragment that could sever the internal carotid in cavernous sinus -----> dural hematoma.

MENINGEAL ARTERIES: Arteries that *supply the meninges and bone* -- not the brain per se.

1. **Middle Meningeal Artery** is a branch off the first part of the Maxillary. It is the principle supplier to the dura.
2. Anterior Meningeal Artery
3. Posterior Meningeal Artery

HEMATOMA: Bleeding within and around the meningeal layers

1. **EPIDURAL HEMATOMA:** Middle Meningeal Artery is easily cut with a skull fracture. This will put pressure in the epidural space and smush the brain.
 1. Flow of blood will go through dura superficially. The extent of the hematoma is limited by suture lines.
2. **SUBDURAL HEMATOMA:** Blood flow will not stop at the skull sutures in this case. However, hematoma usually will not cross the midline.
3. **SUBARACHNOID HEMATOMA:** Blood in this space intermixes with CSF and can lead to headache, stiff neck, and loss of consciousness.
 1. Unlike the ones above, *these are very painful.*
4. **INTRACEREBRAL HEMORRHAGE:** Results in death or paralysis by stroke.

INTERNAL CAROTID ARTERY: Major supplier of blood to the brain.

1. **PATHWAY:** Common Carotid -----> Internal Carotid -----> Into the **Foramen Lacerum** -----> medially to Carotid canal -----> then Anteriorly *through Cavernous Sinus* -----> Then superiorly again.

CIRCLE OF WILLIS: The anastomotic arterial connections supplying the cranial cavity. The two main supplies to the brain are the *Internal Carotid* and *Vertebral Arteries*, and they communicate through the Circle of Willis

- Branches of the VERTEBRAL ARTERY
 - Both Left and Right Vertebrals give off **Posterior Inferior Cerebellar** arteries
 - Then the two Vertebral Arteries converge to form the singular **Basilar Artery**
 - Basilar Artery gives off the **Anterior Inferior Cerebellar** and **Superior Cerebellar** arteries.
 - The Basilar Artery then becomes the **Posterior Cerebral Artery**.
- **POSTERIOR COMMUNICATING ARTERY** connects the Posterior Cerebral (from Basilar) to the Internal Carotid Artery. This is the *major anastomosis between the Carotid and Vertebral arterial channels*.
- Branches of the INTERNAL CAROTID
 - **Middle Cerebral Artery**
 - **Anterior Cerebral Artery**
- **ANTERIOR COMMUNICATING ARTERY:** Connects the Anterior Cerebral Arteries to each other. This is the *major anastomosis of the Right and Left Internal Carotids with each other*.

VENTRICLES OF THE BRAIN: Cerebrospinal fluid is produced in the ventricular system in the brain.

- **CHOROID PLEXUS:** Specialized tissue within the **Lateral, Third, and Fourth Ventricles**, that makes cerebrospinal fluid.
- **Median and Lateral Apertures:** Holes that drain the cerebrospinal fluid down into the spinal column.
- **Interventricular Foramen:** A hole that connects the *Lateral Ventricle* to the *Third Ventricle*.
- **Cerebral Aqueduct:** A hole that connects the *Third Ventricle* to the *Fourth Ventricle*.
- Cerebrospinal fluid is continuous with the optic tract, until it reaches the back of the eye.
- Again, cerebrospinal fluid from the ventricles communicates with the *Superior Sagittal Sinus* via Arachnoid Villi penetrating the sinus.

INTERNAL HYDROCEPHALY: The internal buildup of cerebrospinal fluid. There is no feedback inhibitory mechanism for stopping production of cerebrospinal fluid.

- This could be caused by an obstruction at the cerebral aqueduct.

EXTERNAL HYDROCEPHALY: Cerebrospinal fluid buildup outside the CNS. Caused by excess production of CSF, leading to increased intracranial pressure.

THE EYE AND ORBIT

Gross Morphology Eyeball:

1. External Features:

- **CONJUNCTIVA:** Outermost membranous layer covering both the eye and eyelid.
 - **Palpebral Conjunctiva:** Conjunctiva covering eyelid.
 - **Bulbar Conjunctiva:** Conjunctiva covering eyeball.
 - **Superior Conjunctival Fornix:** Superior limit of conjunctival layer, between eyelid and eyeball.
 - **Inferior Conjunctival Fornix:** Inferior limit of conjunctival layer, between eyelid and eyeball.
- **CANTHUS:** Medial and Lateral. The two corners of the eye, where the upper and lower eyelids meet.

2. Outer Layer of Eyeball

- **BULBAR SHEATH (TENON'S CAPSULE):** A connective-tissue capsule enclosing the eye, right outside the sclera of the eye.
 - **Medial and Lateral Check Ligaments:** These ligaments are extensions of the Bulbar Sheath. They connect to the medial and lateral *periorbita* (periosteum) of the orbit, to hold the eyeball in place.
- **SCLERA:** Dense white connective tissue *continuous with the dura mater of the optic nerve and brain*.
 - The oculomotor muscles insert into the sclera.
- **CORNEA:** The clear central part of the sclera, anterior to the pupil and iris. The cornea is continuous with the sclera.
 - The cornea is avascular, but there are pain fibers from the Ophthalmic N. (V^1)
 - The cornea receives O_2 from the air, thus contact lenses should be gas permeable.
 - Cornea transplants can be done successfully, because the cornea is an *immunologically privileged site*.
- **ANTERIOR CHAMBER** between the cornea and the iris, filled with **Aqueous Humor**.
- **CANAL OF SCHLEMM:** Drains the aqueous humor out of the anterior chamber into the venous blood.

3. Middle Layer of Eyeball

- **CHOROID:** Highly vascular compartment (containing ciliary arteries), sitting between the sclera and the retina proper.
- **PUPIL:** The opening of the iris, which allows light into the eye.
- **IRIS:** Pigmented part of the eyeball, surrounding the pupil.
 - Contains the two intrinsic ciliary muscles: *Dilator Muscle* (sympathetic) and *Sphincter Muscle* (parasympathetic)
- **LENS:** The lens is deformable and has a **natural curvature** which is modulated by zonular fibers and ciliary muscle.
 - **Presbyopia:** The loss of the ability of accommodation. The lens becomes less elastic with old age, resulting in far-sightedness.
 - The more the lens is rounded up, the closer up it can focus, in a gist.
- **CILIARY BODY:** *Produces aqueous humor*, which is secreted into the anterior chamber.
- **CILIARY MUSCLE:** It surrounds the lens and is connected to the lens through **zonular fibers**.
 - It contracts zonular fibers -----> allow lens to increase its natural curvature -----> **accommodation** for near-vision.
- **ZONULAR FIBERS:** Also known as *Suspensory ligaments of the lens*, they connect the lens to the ciliary bodies on either side.

- Tension of zonular fibers make the lens slightly **flattened**, to allow it to gaze at distant objects.
- **ACCOMMODATION:** Contraction of the ciliary muscle to view close-up objects.
 - Ciliary muscle contracts -----> Zonular fibers *lose tension* by pulling toward the anterior chamber of the eye -----> the lens *increases its curvature* due to its natural inherent elasticity -----> light is more highly refracted -----> **close-up objects** come into focus.

4. Inner Layer of Eyeball:

- **VITREOUS BODY:** Filled with gelatinous proteoglycans, vitreous humor, in the posterior chamber of the eye.
- **RETINA**
 - **NEURAL RETINA**
 - **PIGMENTED RETINA**

Gross Morphology of the Eyelid:

1. CILIA: Eyelashes.

- **CILIARY GLANDS:** *Sebaceous Glands* that lubricate the eyelashes.
 - **Sty:** Infection of the sebaceous ciliary glands, usually resulting from obstruction.

2. TARSAL PLATE: Connective tissue core of the eyelid.

- Two muscles insert on the tarsal plate to control the eyelid:
 - *Tarsal Muscle (smooth)*
 - *Levator Palpebrae Superiores*
- *Palpebral part of Orbicularis Oculi* also helps to raise the eyelid, but its insertion is superior to the tarsal plate.
- **Medial and Lateral Palpebral Ligaments:** Connect the tarsal plate to each wall of the orbit.
- **TARSAL GLANDS:** Secrete fatty lubricants to keep the eyelids from sticking to each other.
 - **Chalazion:** An infection of the tarsal glands.

3. ORBITAL SEPTUM: Extends up from tarsal plate and hooks onto the bony border of the orbit on either side. It effectively separates the front of the orbit (very anterior part) from the rest of the orbit.

4. BLINKING: The UPPER EYELID does all the work in opening and closing the eyelid. The lower eyelid is not controlled by an muscles, but only by gravity.

Lacrimal Apparatus:

- **Lacrimal Gland:** The superior and lateral part of the orbit, consisting of two parts: An *orbital* and *palpebral* part.
 1. They secrete tears into the *superior conjunctival fornix* of the eye.
 2. Tears go over the cornea of the eye every time you blink or close your eyelid.
- **Lacrimal Caruncle:** Medial Canthus of the eye, the location of the **Lacrimal Lake**, where tears accumulate *after they have coated the surface of the cornea*.
- **Lacrimal Puncti:** Two openings in the **Lacrimal Papilla** (bumps), on either side of the Lacrimal Caruncle. These holes take up tears by a vacuum motion every time you blink.
- **Lacrimal Canaliculus:** The canal that conducts tears from the Lacrimal Puncti to the Lacrimal Sac.
- **Lacrimal Sac:** Directly proximal to the Nasolacrimal Duct. Tears pool up here until they are ejected into the nasolacrimal duct and onto the nose.
- **Nasolacrimal Duct:** The duct which allows tears to conduct from the eye to the nose. Crying and tearing causes sniffing due to overflow of the nasolacrimal duct.
- Overall flow of tears: Lacrimal Gland -----> 8 to 10 lacrimal ducts -----> Superior Conjunctival Fornix -----> surface of cornea -----> Lacrimal Lake -----> Lacrimal Puncti -----> Lacrimal Canaliculi -----> Lacrimal Sac -----> Nasolacrimal Duct -----> Nasal Cavity, under the Inferior Turbinate.

THE ORBIT:

1. Borders:

- Superior: Frontal bone and small part of Lesser Wing of the sphenoid
- Lateral: Greater wing of the sphenoid and frontal process of the Zygomatic bone
 - Lateral walls are almost 90° from each other.
- Medial: Orbital lamina of the ethmoid bone and lacrimal bones.
 - Medial walls are approximately parallel to each other.
- Inferior: Maxillary bone.

2. FORAMINA associated with the orbit:

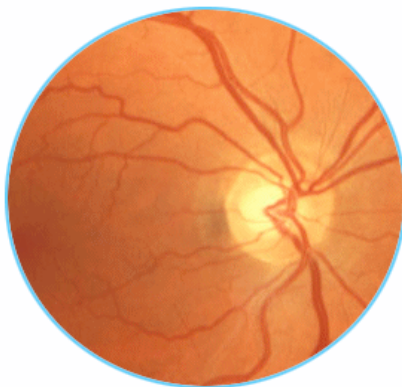
- **SUPERIOR ORBITAL FISSURE:** Between the lesser and greater wings of the sphenoid bone.
 - It transmits the *Superior Ophthalmic Vein*.
 - It transmits *all innervation to the orbit, EXCEPT the Optic Nerve (II):* Oculomotor (III), Trochlear (IV), Ophthalmic (V^1), and Abducens (VI)
- **OPTIC CANAL:** In the Lesser Wing of Sphenoid, superomedial to the superior orbital fissure.
 - It transmits the *Optic Nerve (II)*
 - It transmits the *Ophthalmic Artery*, a branch from the Internal Carotid.
- **INFERIOR ORBITAL FISSURE:** Carries the *Maxillary Nerve (V^2)* along the bottom surface of the orbit.
- **INFRAORBITAL FORAMEN:** The lower medial corner of the orbit, in the orbital part of the maxillary bone.
 - It transmits the *Infraorbital Nerve (V^2)* *out of the orbit*.
 - It transmits the *Infraorbital Artery* -- an anastomotic branch between the Angular and Maxillary Aa. (both of which are off the External Carotid).
- **ETHMOID FORAMEN:** Anterior and posterior foramina in the medial wall, transmitting structures that are going from orbit to the ethmoid air sinuses and nose:
 - *Anterior and Posterior Ethmoid Arteries*, from Ophthalmic Artery
 - *Anterior and Posterior Ethmoid Nerves*, from Nasociliary Nerve (V^1)

COMMON ANNULAR TENDON: The common ring-shaped origin of the extrinsic eye muscles. It surrounds both the Optic Canal and Superior Orbital Fissure.

- The common tendon actually sits *medial* and not exclusively posterior to the eyeball.
- All four rectus muscles originate from the tendon itself.
- The two oblique muscles have origins near the tendon but not in it.

THE H-TEST: Explains the function of the extrinsic eye-muscles. To test for functionality of all muscles (and therefore cranial nerves III, IV, and VI), have the patient look to the left and right, and then up and down. Then use the following guide:

FUNDUS OF THE EYE: What you see looking through an ophthalmoscope



- When looking through an ophthalmoscope, you are looking at the posterior portion, or **fundus** of the retina.
- **OPTIC DISC:** Medial, circular area where arteries and veins enter the eye.
- **MACULA LUTEA:** Lateral to the optic disc, containing the **FOVEA CENTRALIS** in its center. *This is the area of greatest visual acuity of the retina -- the center of focus.*
 - This is the area where rods and cones are most highly exposed, i.e. the least amount of neural retina is covering them.

Arterial Supply to the Eye: **OPHTHALMIC ARTERY** provides almost all blood supply to the eye. It is the first branch off the Internal Carotid, and it enters through the Optic Canal. It's branches:

1. **Posterior Ciliary Arteries** -----> choroid layer behind the eye, but not the retina.
2. **Supraorbital Artery**
3. **Supratrochlear Artery**
4. **Lacrimal Artery**
5. **Anterior and Posterior Ethmoidal Arteries**
6. **CENTRAL RETINAL ARTERY:** The *only blood supply to the neural retina*. It pierces the dura mater of the optic nerve to supply the neural retina.
 - It branches at the optic disc of the retina.
 - Loss of blood supply from the central retinal results in blindness.

VENOUS DRAINAGE: **Superior and Inferior Ophthalmic Veins** drain the eye. They join *before* the Superior Orbital Fissure ----> through the superior orbital fissure -----> facial vein AND cavernous sinus / Pterygoid Plexus.

- *Thus once again the ophthalmic veins provide a crucial (and dangerous) anastomosis between the face and cranial cavity.*

CLINICAL PROBLEMS ASSOCIATED WITH THE EYES:

- **Sty:** Sebaceous glands of the eyelashes become blocked and infected.
- **Chalazion:** Blockage of one of the tarsal glands, resulting in a lump in the eyelid.
- **Conjunctival Hyperemia:** Bloodshot eyes. Local irritation yields high perfusion in the *bulbar conjunctiva* of the eye.
- **Conjunctivitis:** Pink-eye. Inflammation of the conjunctiva.
- **Glaucoma:** Excessive pressure within the eye.
 - *Closed-Angle Glaucoma* is due to blockage of fluid from the Canal of Schlemm (aqueous humor can't drain).
 - Intraocular pressure is tested by blowing a high-pressure jet of air on the eyeball and measuring the deformity of the cornea.
- **Exophthalmos:** Bulging eyes, usually resulting from Grave's Disease. This is due to extra body in extrinsic eye muscles.
 - It can also result from internal carotid rupture in the cavernous sinus.
- **Cataract:** A loss of transparency of the lens, common in old age.
- **Papilledema:** *Excessive CSF pressure* causing the optic disc to swell, causing venous blood to pool on the surface of the retina.
 - This can be diagnosed *with an ophthalmoscope*.
- **Venous Nicking:** *High blood pressure* causes ophthalmic arteries to swell, which in return restricts venous return.
 - The arteries and veins "cross" each other, so swelling of the arteries impedes on the veins.
 - This again can be seen *with an ophthalmoscope*.
- **Horner's Syndrome:** Loss of sympathetic innervation to the head. Its effects on the eyes are as follows:
 - *Ptosis* -- Upper eyelid droops.
 - *Anhydrosis* -- No sweat above the neck.
 - *Miosis* -- Constriction of pupil from unchecked parasympathetics.

THE TRIANGLES OF THE NECK

BONY LANDMARKS OF NECK:

- **HYOID BONE:** Suspended in space by the hyoid muscles. Right below the floor of the mouth.
- **THYROID CARTILAGE:** It forms the **Laryngeal Prominence**, or Adam's Apple, overlying the Thyroid Gland and Larynx.
- **CRICOID CARTILAGE:** Cartilaginous ring right below the Thyroid Cartilage.

FASCIAL LAYERS OF THE NECK:

1. **Investing Fascia:** Outermost layer below skin. Encloses the *Sternocleidomastoid* and *Trapezius* muscles.
2. **Pretracheal Fascia:** Anterior to the spine, completely enclosed within investing fascia. Contents:
 - Thyroid Gland
 - Trachea
 - Esophagus
3. **Prevertebral Fascia:** Enclosing the musculature surrounding the spine.
4. **Carotid Sheath:** Completely enclosed within investing fascia, on either side of the pretracheal fascia. Contents:
 - *Common Carotid Artery*
 - *Internal Jugular Vein*
 - *Vagus Nerve*
5. **Retropharyngeal Space:** Potential space between the pretracheal fascia and prevertebral fascia.

POSTERIOR TRIANGLE OF THE NECK: That region posterior to the Sternocleidomastoid muscle, and anterior to the Trapezius.

1. **DANGER ZONE:** That part of the posterior triangle inferior to the Spinal Accessory Nerve. It contains:
 - The Spinal Accessory Nerve (XI)
 - Brachial Plexus
2. **VEINS OF POSTERIOR TRIANGLE: EXTERNAL JUGULAR VEIN** = The union of the **Retromandibular** and **Posterior Auricular Veins**
 - Eventually pierces investing fascia but not prevertebral fascia.
 - It can fill and become visible from holding breath, or from congestive heart failure.
 - Most of the facial veins drain into the external jugular.
 - **Transverse Cervical** (from back of danger zone) and **Suprascapular veins** drain into External Jugular.

CERVICAL PLEXUS. Formed from ventral primary rami of cervical vertebral levels. All of below come off of Cervical Plexus and *penetrate investing fascia of the posterior triangle*, but not superficial fascia.

1. A set of cutaneous nerves from this plexus *penetrate the investing fascia* in this region, to innervate the posterior triangle.
2. **Lesser Occipital Nerve:**
 - The Greater Occipital Nerve is *not from the Cervical Plexus, as it is from the Dorsal Primary Ramus* of C1.
 - It runs along the posterior of the Sternocleidomastoid muscle.
3. **Great Auricular Nerve** -- runs along the External Jugular.
4. **Transverse Cervical Nerve**
5. **Supraclavicular Nerve**
6. **Phrenic Nerve:** Runs *on top of (adhered to) the anterior scalene muscle*
7. **ANSA CERVICALES:** Originates from C1-C3. Supplies motor innervation to the strap muscles.
 - It surrounds the *Carotid Sheath*.
 - **Superior Root:** Some branches of the **Hypoglossal Nerve (XII)** get mixed up with Ansa Cervicales C1 fibers -----> innervate the Geniohyoid muscle.
 - As a result, parts of the *superior root tag along the Hypoglossal to get to the strap muscles*.
 - These muscles tag along as the nerve enters back through the Hypoglossal Canal.
 - **Inferior Root**, containing lower cervical levels.

BRACHIAL PLEXUS: Travels *between the Anterior and Middle Scalene muscles* to reach the axilla.

- **CERVICAL RIB:** The presence of a "cervical rib" coming out above T1 at C7 can impinge on the Brachial Plexus and/or the Subclavian Artery, causing problems.

ANTERIOR TRIANGLE OF THE NECK: The anterior region of the neck, between the two heads of the Sternocleidomastoid.

1. SUBMANDIBULAR TRIANGLE

- Borders:
 - *Posterior belly of Digastric:* Lateral border
 - *Anterior belly of Digastric:* Medial border
 - *Mandible:* Superior border
- Contents:
 - Facial Artery
 - Hypoglossal Nerve (XII)
 - Submandibular Salivary Glands
 - Muscles: Digastric, Mylohyoid, Hyoglossus

2. CAROTID TRIANGLE

- Borders:
 - *Superior Belly of the Omohyoid:* Medial Border
 - *Posterior Belly of the Digastric:* Superior Border
 - *Sternocleidomastoid:* Lateral Border
- Contents: This triangle overlies the **Bifurcation of the Carotid**. It contains the Carotid Sheath, as well as the external jugular vein outside of the carotid sheath.
- Layers: As you cut through the Carotid Triangle, you find the following in order from superficial to deep:
 - **External Jugular Vein**, outside of investing fascia
 - Investing Fascia
 - **Carotid Sheath:**
 - **Internal Jugular Vein** is *superficial and lateral* to the common carotid.
 - **Common Carotid Artery**

3. SUBMENTAL TRIANGLE

4. MUSCULAR TRIANGLE:

- Borders:
 - *Superior Bellies of the Omohyoid* Lateral borders
 - *Midline of the neck:* Medial borders
- Contents: **The Strap Muscles --**

ARTERIES OF THE NECK:

- **BRANCHES OF THE EXTERNAL CAROTID:** Following is a complete list of principle branches off the External Carotid.
 - 3 anterior branches
 - **Superior Thyroid Artery** -- Thyroid gland and part of anterior neck
 - **Lingual Artery** -- to tongue
 - **Facial Artery**
 - 1 medial branch
 - **Ascending Pharyngeal Artery** -- to pharynx
 - 2 posterior branches
 - **Occipital Artery** -- back of neck and behind ear
 - **Posterior Auricular Artery** -- behind and around ear

- 2 terminal branches -- External Carotid ends as these two terminal branches
 - **Maxillary Artery** -- goes onto palate, nose, infraorbital region
 - **Superficial Temporal Artery** -- blood supply to temporal scalp
 - **THE THYROCERVICAL TRUNK:** Comes directly off the Subclavian.
 - **Inferior Thyroid Artery** -- not the Superior Thyroid!
 - **Transverse Cervical Artery**
 - **Ascending Cervical**
 - **COSTOCERVICAL TRUNK** -- Comes off Subclavian and gives off a Deep Cervical Artery which goes to anastomose with the Occipital Artery.
-

THE NOSE AND PARANASAL SINUSES

External Features:

- **Septal Cartilage:** Continuation of the vertical plate of the ethmoid bone.
- **Lateral Nasal Cartilage:** Spawning laterally from each side of the septal cartilage.
- **Great Alar Cartilage:** U-shaped, each with a **lateral and nasal crus**, defining the **nares** (nostrils).

BONES OF NASAL CAVITY:

- **ETHMOID BONE**
 - **Perpendicular Plate** forms the superior part of nasal septum and articulates with **septal cartilage**.
 - **Cribriform Plate:** Transverse plate forming the superior border of the nasal cavity, and containing **cribriform foramina** through which Olfactory nerves pass.
- **VOMER:** The posteroinferior border of the nasal septum.
 - It articulates with the **Nasal Crests** of the Maxilla and Palatine bones.
- **LACRIMAL BONES:** Paired bones forming part of the Middle Meatus of each nostril. The *lacrimal sacs* are opposite these bones.

OLFACTORY APPARATUS: There is a *ciliated mucous membrane* at the *top* of the nasal cavities, along the lateral and medial walls.

- The cell bodies of the **Olfactory Nerves (I)** actually sit *within the Olfactory Mucosa* on the superior part of nasal cavity.
- The nerves go through foramina in the **Cribriform Plate** to **Olfactory Tracts** on the other side.

CONCHAE BONES (TURBINATES) and NASAL OPENINGS: All openings come out of the *lateral wall* of each septum. Conchae provide for *increased surface area and turbulence* for humidifying and "mixing" the air we breathe.

- **Sphenoethmoidal Recess:** Superior to the Superior Conchae, in the posterosuperior portion of the nasal cavity.
 - It contains the *opening of the Sphenoid air sinus*.
 - The Sphenoid Air Sinus drains into two bilateral *Sphenoid Ostia* on either side of the recess in the nasal cavity.
- **SUPERIOR CONCHAE:** An extension of the ethmoid bone coming out of the lateral wall of the nasal cavity.
- **SUPERIOR MEATUS:** Recess between superior conchae and middle conchae.
 - It contains the *opening of the Posterior Ethmoid air sinus*.
- **MIDDLE CONCHAE:** An extension of the ethmoid bone coming out of the lateral wall of the nasal cavity.
- **MIDDLE MEATUS:** Recess between middle conchae and inferior conchae.
 - **Ethmoid Bulla:** Raised portion of ethmoid bone in middle meatus.
 - It contains the *opening of the Middle Ethmoidal air sinus*, but this is variable.
 - These "air cells" are a series of little openings for the Ethmoid Sinus going through the Ethmoid Bulla of the ethmoid bone.
 - **Semilunar Hiatus:** The opening just anteroinferior to the Ethmoid Bulla.

- It contains the *opening of the Maxillary Sinus.*
 - It contains the *opening of the Anterior Ethmoidal air sinus*
- **Infundibulum:** At the anterosuperior end of the semilunar hiatus.
 - It contains the *opening of the Frontal Sinus.*
- **Uncinate Process:** The anteroinferior edge of the semilunar hiatus.
- **Sphenopalatine Foramen:** It is located directly behind the middle meatus, in the posterosuperior part of nose, right in front of Sphenoid air sinus.
- **INFERIOR CONCHAE:** A *separate bone* attached to the lateral wall of the nasal cavity.
- **INFERIOR MEATUS:** Recess between inferior conchae and *palatine process* (hard palate) of Maxilla.
 - It contains the *opening of the Nasolacrimal Duct.*

ARTERIAL SUPPLY TO THE NOSE and NASAL CAVITY:

- **ANTERIOR AND POSTERIOR ETHMOID ARTERIES:**
 - Both of them come from the Internal Carotid via the Ophthalmic Artery.
 - The Ethmoid Arteries leave the orbit through anterior posterior ethmoid foramina in the cribriform plate of the ethmoid bone.
 - After leaving the orbit, they travel ***through the anterior cranial fossa, underneath the dura before going through the Ethmoid Foramina.***
 - That means that overall blood supply from the internal carotid is as follows: **Internal Carotid Artery -----> Middle Cranial Fossa -----> Optic Canal -----> Ophthalmic Artery -----> Ethmoid Arteries ----->** through anterior posterior ethmoid foramina in cribriform plate -----> *Anterior Cranial Fossa -----> Anterior and Posterior Ethmoid Foramen -----> Nasal Cavity*
 - Both of the Ethmoid Arteries divide into *septal and lateral branches*, to supply the medial and lateral walls of the nasal cavity.
- Principle Blood Supply to NOSE:
 - INFERIOR 1/3 OF NOSE -- External Carotid:
 - Facial Artery -----> Angular Artery -----> **Lateral Nasal Artery**
 - Sphenopalatine Artery -----> **Posterior Lateral Nasal Arteries**
 - Sphenopalatine Artery -----> **Posterior Septal Artery**
 - SUPERIOR 1/3 OF NOSE -- Internal Carotid: Ophthalmic Artery -----> **Dorsal Nasal Artery** -----> bridge of the nose.
- Additional Blood Supply to NOSE: This covers the INFERIOR 2/3 OF NOSE with additional blood supply.
 - Internal Carotid -----> Ophthalmic Artery -----> Anterior Ethmoidal Artery -----> Lateral Branch of Anterior Ethmoid Artery -----> **External Nasal Artery**
 - External Carotid -----> Maxillary Artery -----> **Infraorbital Artery**
- Principle Blood Supply to the NASAL CAVITY:
 - **Anterior Ethmoidal Artery**, from Ophthalmic, is the largest contributor.
 - **Posterior Ethmoidal Artery** contributes a little less in the posterior region.
 - **Sphenopalatine Artery** is a terminal branch of the Maxillary Artery: Maxillary -----> **Sphenopalatine Foramen** -----> Sphenopalatine Artery -----> Lateral and Septal branches
- INTERNAL/EXTERNAL CAROTID ANASTOMOSES IN THE NOSE:
 - **Angular Artery** (from Facial) <=====> **Dorsal Nasal (aka Infratrochlear) Artery** (from Ophthalmic)
 - Lateral and Septal Branches of **Ethmoid Arteries** (from Ophthalmic) <=====> Lateral and Septal Branches of **Sphenopalatine Artery** (from Maxillary)

SPHENOPALATINE FOSSA: The sphenopalatine fossa houses the sphenopalatine ganglion. Underneath the Zygomatic Arch, from lateral to medial, we have:

- Temporal Fossa: Home of the Temporalis muscle.
- Infratemporal Fossa: Home of the principle branches of the Maxillary Artery
- Sphenopalatine Fossa: Home of the Sphenopalatine Ganglion. Boundaries of Sphenopalatine Fossa are as follows:
 - Posteriorly: Lateral plate of Pterygoid
 - Anteriorly: Maxillary bone
 - Medially: Palatine bone
 - Laterally: open

INNERVATION OF THE NASAL CAVITY:

- **Nasopalatine Nerve:** From Maxillary (V2).
 - It is given off at the Sphenopalatine Ganglion.
 - It carries sympathetics from the **Deep Petrosal Nerve** and parasympathetics from the **Greater Petrosal Nerve**
 - It enters the nose through the **Sphenopalatine Foramen**, where it gives off lateral and septal branches to provide *visceral motor (GVE)* innervation to the nasal mucosa.
 - Sympathetic (deep petrosal) = inhibition of nasal mucosa
 - Parasympathetic (greater petrosal) = secretomotor stimulation of nasal mucosa
 - It will continue down **Septal Wall** of nose, through the **Incisive Foramen**, right behind the incisors (front teeth). There it will provide sensory innervation to the anterior portion of the hard palate.
- **Anterior Ethmoid Nerve:** Provides sensory innervation to internal nose, plus some innervation to external nose.
 - It divides into **Medial and Lateral Internal Nasal Nerves**.
- **Infraorbital:** From Maxillary (V2), provides some sensory innervation to inferior part of external nose via External Nasal branches.
 - The Infraorbital may anastomose with the **Infratrochlear**, from Ophthalmic (V1), over the surface of the nose.
 - So, the external surface of the nose potentially has dual innervation.

THE PARANASAL SINUSES:

- **DEVELOPMENT:**
 - Sinuses develop as evaginations of the nasal mucosa. Consequently they have mucous membrane that is continuous with the nasal mucosa.
 - Newborns generally do not have sinuses.
- **NASAL MUCOUS:**
 - Mucous can buildup in the sinuses from swelling, this tends to plug the area around the opening of the sinuses into the nose (i.e. the Middle Meatus) and impede on the passage of air through the nose as well.
 - **Cilia** of mucosal cells will trap particles in the air as it passes through the turbinates (conchae).
 - The cilia push the mucous toward the nasopharynx, and we end up swallowing the stuff.
 - If there is overload, the cilia can't push all of it and we get a runny nose.
- **The Four Sinuses:**
 - **Frontal Sinus**
 - **Sphenoid Sinus**
 - **Ethmoid Sinus**
 - **Maxillary Sinus**
- **Maxillary Sinus** is the "Achilles Heel" -- the only sinus whose *opening is superior to the sinus itself*, such that it can't easily drain into the nose due to gravity itself.
 - This is why, when you lay on one side of your body with a cold, you tend to clog the "downhill" side of your nose.

CLINICAL STUFF ABOUT THE NOSE AND PARANASAL SINUSES:

- **Nose Bandages:** Worn across the bridge, they are supposed to help the nasal aperture open, to aid the intake of air.
- **KIESSELBACH'S (LITTLE'S) PLEXUS: Nose Bleeds.** The plexus is located in the vestibule of the nose, on the nasal septum. It is an anastomotic network of four blood vessels, and nosebleeds are especially common in the area:
 - Septal Branch of the **Superior Labial Artery**
 - Septal Branch of the **Anterior Ethmoid Artery**
 - **Sphenopalatine Artery**
 - **Greater Palatine Artery** branched which sneak up through the incisive canal.
- **Runny Nose:** Overload or backflow of mucous in the nose, resulting basically from too much mucous.
- **SINUSITIS:** Inflammation of the sinuses. Very common.
 - Typically a bacterial infection.
 - Diagnostic Findings with sinusitis:
 - **Transillumination** = x-ray technique to visualize the sinuses and see whether they are filled with mucous.
 - Purulent Nasal Discharge
 - Sinus Tenderness
 - Symptoms: Typical of a cold -- runny nose, headache, facial pain, cough.
 - REFERRED PAIN: Where the pain is can indicate which sinus is inflamed:

- Maxillary Sinus: Upper teeth or alveolar pain (this could also be a dental problem, however)
- Frontal Sinus: Headache in forehead and around eyes
- Sphenoid Sinus: Headache on forehead and on top of head
- Ethmoidal Sinus: Headache in lateral portion / temporal region.
- A *deviated septum* or *misplaced turbinates* may cause **chronic sinusitis**. Endoscopic surgical intervention is one form of treatment.
- **Rhinorrhea**: Leakage of CSF out of the nose. Most typically the result of severe trauma.
 - Probably from a ruptured cribriform above the ethmoid air sinus, exposing dura of the anterior cranial fossa.
 - You can do a lumbar puncture and inject fluorescent dye into the CSF, to localize the source of the leakage.
- **Broken Nose**: Generally a fracture of the nasal bones (the bridge), or the articulation of the nasal bones with the nasal cartilage.
 - Treatment: Anesthetize and insert a speculum into the nose to push to septum over while finger is used to push the nasal bones over. It may be painful no matter what due to rich nerve supply.

THE MOUTH AND ORAL REGION

Stratified Non-Keratinized Epithelium: Is on the inner surface of the lip.

Stratified Keratinized Epithelium: Is the gingiva attached to the teeth, more tightly bound than that of the lip, but continuous with it.

Ducts into the Mouth:

- **Submandibular Duct**: Two openings sublingually on either side of the lingual frenulum.
- **Sublingual Duct**: A series of openings under the tongue, spreading laterally from the submandibular ducts.
- **Parotid Duct**: Opens on the side of the mouth, *opposite the second molar tooth*.

THE MANDIBLE:

- **Mylohyoid Line**: On inner surface of mandible, a point of attachment of the Mylohyoid muscle. It runs from Symphysis Menti to the area around third molar.
- **Submandibular Fossa**: The region below the mylohyoid line, containing the submandibular salivary gland.
- **Mental Spines**: Attachments of genioid muscle.
- **Lingula**: Overhanging the mandibular foramen, it is the attachment of the sphenomandibular ligament.
- **Mandibular Foramen**: Transmits inferior alveolar nerve, artery, and vein, just under the lingula.

TEMPOROMANDIBULAR JOINT: The articulation of the head of the **condylar process of mandible** with **zygomatic process of temporal**.

- Two types of movement at TMJ Joint:
 - **Hinge Movement**: Occurs between the head (condyle) of the mandible and the **inferior surface** of articular disc.
 - **Gliding Movement**: Occurs between temporal bone and the **superior surface** of the articular disc.
- **DISLOCATED JAW**: The condylar process of mandible slides anterior to the articular tubercle of the temporalis, locking the jaw open.
 - Treatment: Protect the teeth (and your fingers) and push down on the mandible, and it will forcefully snap back into place.
- Ligaments:
 - **Lateral Temporomandibular Ligament**: More or less just a thickening of the articular capsule.
 - **Sphenomandibular Ligament**: Goes from spine of sphenoid bone to lingula of the mandible. Helps limit the forward motion of the mandible.
 - **Stylomandibular Ligament**: Styloid Process <====> Angle of Mandible Helps limit the forward motion of the mandible.

MANDIBULAR FORAMEN: Inferior Alveolar Nerve, Artery, and Vein enter it to gain access to lower teeth. Located on inner surface of mandible, right under the Lingula.

- Dentists will often inject anesthesia right here, to numb the inferior alveolar nerve.
- They find the location of the mandibular foramen by using visual cues to locate the *lingula* on the interior of the mandible.

INFRATEMPORAL FOSSA: The region between the zygomatic arch of the temporalis and the lateral pterygoid plate of the sphenoid.

- Major structure to traverse this fossa: Maxillary Artery.

PTERYGOPALATINE FOSSA is medial to the Infratemporal Fossa, in the region of the pterygoid plates. The following structures can be found there:

- Major structures to be found in this fossa:
 - Medial and Lateral Pterygoid Muscles
 - Sphenopalatine ganglion.

MAXILLARY ARTERY: From the region of the infratemporal fossa, it has three principle components.

- **FIRST PART** *mainly supplies structures in cranium and middle ear.*
 - **Anterior Tympanic Artery** to middle ear
 - **Deep Auricular Artery** to inner ear
 - **Middle Meningeal Artery** goes through *Foramen Spinosum* in the spine of the sphenoid to reach the middle cranial fossa.
 - **Inferior Alveolar Artery:** Sort of an exception because it doesn't supply cranial fossa.
 - It will eventually go through *Mandibular Foramen* to supply lower teeth.
 - Then it continues through *Mental Foramen* to supply chin and lower teeth.
- **SECOND PART** *mainly supplies the muscles of mastication.*
- **THIRD PART** *supplies hard to reach areas anteriorly.*
 - **Posterior Superior Alveolar Artery** to the upper posterior teeth
 - **Infraorbital Artery** will eventually come out the *Infraorbital Foramen*.
 - **Sphenopalatine Artery** goes through *Sphenopalatine Foramen* to supply blood to lateral nasal wall and then paranasal sinuses.
 - **Descending Palatine Artery:** To hard and soft palate.
 - **Artery of the Pterygoid Canal:** Runs with Nerve of Pterygoid Canal.

PTERYGOID PLEXUS: Venous plexus surrounding medial and lateral pterygoid muscles.

- Communicates with Cavernous Sinus.
- Communicates with Facial and Angular veins via the Infraorbital Vein.
- It will also communicate with **retromandibular vein**.

TEETH:

- 10 deciduous teeth and 32 permanent teeth.
- **Enamel** = hard outer surface.
- **Cementum** = the inner aspect of the hard enamel.
- **Dentin** is deep to the enamel and cementum.
- **Pulp** is deep to the dentin and contains the nerves and vessels.

TONGUE:

- **Filiform Papillae:** Taste receptors on anterior 2/3 of tongue
- **Fungiform Papillae:** Mushroom-like taste receptor on the anterior 2/3 of tongue.
- **Circumvallate Papillae:** Taste buds on the posterior 1/3 of tongue.

- **Sulcus Terminalis:** Divides posterior from anterior parts.
- **Foramen Cecum:** Depression in the midline of tongue, remnant of primitive **thyroglossal duct**.

BLOOD SUPPLY TO TONGUE: **Lingual Artery**, Branch off the External Carotid, usually the second branch. Its principle branches in the mouth:

- **Dorsal Lingual Artery** -- remember dorsum of tongue is the top part that can be seen easily.
- **Deep Lingual Artery** to anterior 2/3 of tongue
- **Sublingual Artery** to floor of mouth

THE PHARYNX

Layers of the Pharynx:

- Oral mucosa and submucosa
- **Pharyngobasilar Fascia**
- Muscular Layer -- the pharyngeal muscles
- **Buccopharyngeal Fascia:** A tough external fascia that allows pharynx to move relative to neighboring structures (i.e. vertebral column, esophagus, carotid sheaths)

MEDIAN RAPHE: Common muscle attachment of pharyngeal constrictors. Located on the posterior of the pharynx.

PHARYNGEAL MUSCLES: What emerges between each of the pharyngeal constrictors

- SUPERIOR PHARYNGEAL CONSTRICTOR
 - **Stylopharyngeus Muscle**
 - **Glossopharyngeal Nerve** -- this is a good landmark for identifying this nerve.
 - **Lingual Artery**
- MIDDLE PHARYNGEAL CONSTRICTOR
 - **Superior Laryngeal Nerve (Internal Branch)**
 - **Superior Laryngeal Artery and Vein**
- INFERIOR PHARYNGEAL CONSTRICTOR
 - **Recurrent Laryngeal Nerve**
 - **Inferior Laryngeal Artery**

PTERYGOMANDIBULAR RAPHE: Tendinous connection between the hamulus of the lateral pterygoid plate and the mylohyoid line of the mandible.

- It serves as the origin of two important muscles: **buccinator muscle** and **superior pharyngeal constrictor**
- It is also the *division between the oral cavity and oropharynx*.

EUSTACHIAN TUBES: They equilibrate pressure between the middle ear and atmosphere, via the throat.

- Openings of the eustachian tubes are found in the Nasopharynx, at the *posterolateral aspect*.
- **Torus Tubarius:** The tissue surrounding the eustachian tube.

TONSILS: WALDEYER'S RIM -- a "ring" of tonsils surrounding the naso and oropharynx.

- **Pharyngeal Tonsil** -- Single lymph "node" on posterior of nasopharynx. It *samples antigens breathed in through the air and triggers an immune response*.
 - **ADENOID TONSILS:** When enlarged or inflamed, it is termed an adenoid tonsil. This makes it block the nasopharynx in children, forcing them to breathe through their mouth, termed **Adenoid Breathing**.
- **Palatine Tonsil** -- between the palatoglossal and palatopharyngeal arches, on the posterior of the roof of the mouth.
- **Lingual Tonsil** -- on posterior third of tongue

- **Tubular Tonsil:** Tonsils near the opening of the Eustachian tubes.
- **INFLAMED TONSILS:** *Glossopharyngeus Nerve* can pick up referred pain from inflamed tonsils and send the sensory pain to the middle ear.
- **DEEP CERVICAL LYMPH NODES:** All tonsils of Waldeyer's Rim drain into deep cervical lymph nodes.

ARCHES: The **palatine tonsil** is located between the two arches.

- **Palatoglossus Arch:** More anterior and more visible.
- **Palatopharyngeal Arch:** More posterior.

SOFT PALATE: The muscles of the soft palate *separate the nasopharynx from the oropharynx*.

- Raising the soft palate prevents food and liquid from getting in nose and middle ear.
- **SLEEP APNEA:** Can be due to drooping of the tongue or soft palate into the oropharynx, blocking off air to the nose.

BLOOD SUPPLY TO PHARYNX: Mostly from External Carotid

- **Ascending Pharyngeal Artery** directly off the External Carotid.
- Maxillary -----> **Descending Palatine Artery**
- Facial Artery branches:
 - **Ascending Palatine Artery**
 - **Tonsillar Branch** going to tonsils
- Lingual Arteries and Ascending Pharyngeal arteries -- minor contributions.

SWALLOWING:

- STAGE 1
 - Sensory nerves from Lingual (V3) allow you to monitor the position of food in the mouth, to make sure you don't choke.
 - As it moves back down to oropharynx, CN IX starts to sense its position.
 - **Raise the Hyoid Bone** by Stylohyoid and Stylopharyngeus muscles.
- STAGE 2
 - **Soft palate is elevated and tightened** to seal off the nasopharynx from the oropharynx.
 - **Superior Constrictor** then "grabs" the bolus of food and constricts it down pharynx in peristaltic motion.
 - Larynx and pharynx are drawn up and forward.
- STAGE 3
 - The Arytenoid cartilages are drawn forward.
 - Food goes through **piriform fossae**
 - **Epiglottis** is drawn backward to guard tracheal opening. Trachea closes when *Epiglottis moves down and epiglottal folds move together*.
- STAGE 4
 - Inferior Constrictor sends the food down the esophagus.

THE LARYNX

GLOTTIS: Aperture of the larynx, which serves to separate the larynx from the pharynx during swallowing.

- The glottis overlays the respiratory tract (trachea).
- Closing it allows for increase in thoracic / abdominal pressure, for coughing, peeing, pooping, etc.
- **RIMA GLOTTIS:** The opening between the vocal cords, overlying the glottis. The **Lateral Cricoarytenoid Muscle** contracts to open the vocal cords to allow inspiration.

LARYNGEAL CARTILAGES:

- **Thyroid Cartilage** overlies the thyroid gland and composes the Adam's Apple.

- **THYROHYOID MEMBRANE:** Attaches the thyroid cartilage superiorly to the hyoid bone.
 - **Internal Laryngeal Nerve (X)** and **Superior Laryngeal Artery** pierce this membrane.
- **Cricoid Cartilage:** It is the lower edge of the larynx.
 - **Cricothyroid Membrane** attaches cricoid superiorly to thyroid cartilage. It is thickened anteriorly and called the **Cricothyroid Ligament**.
 - The edge of the Cricothyroid Ligament is the **Vocal Ligament**
- **Epiglottic Cartilage (Epiglottis)** -- directly posterior to thyroid cartilage, and overlying the hyoid bone.
 - Attaches to Thyroid Cartilage via **Thyroepiglottic Ligament**
 - Attaches to Hyoid Bone via **Hyoepiglottic Ligament**
 - **Quadrangular Membrane:** Attaches to Arytenoid Cartilages
 - Aryepiglottic Fold is its superior limit
 - Vestibular Ligament (false vocal cord) is its inferior limit
- **Arytenoid Cartilage** -- small paired cartilages on top of the cricoid cartilage
 - There are the *site of attachment of the vocal cords and the muscles that move the vocal cords*.
 - Muscular Process: For muscle attachment
 - Vocal Process: For attachment of **vocal ligaments**
- **Corniculate Cartilage** -- right on top of the apex of the arytenoid cartilage.
- **Cuneiform Cartilage** -- help form the posterior part of the epiglottic fold, along with the corniculate cartilages

VOCAL LIGAMENT: Goes from the Vocal Process of the Arytenoid Cartilage to the inner aspect of the Thyroid Cartilage.

- **CONUS ELASTICUS:** The name of the vocal ligament together with the Cricothyroid ligament.

LARYNGEAL MUCOSA: Lined by respiratory epithelium, but it *converts to stratified epithelium over the vocal cords*.

- This change in cell-type lends itself to cancer, hence **laryngeal cancer** is the most common form of head-and-neck cancer.

BLOOD SUPPLY TO THYROID GLAND:

- External Carotid -----> **Superior Thyroid Arteries**
- Thyrocervical Trunk -----> **Inferior Thyroid Arteries**

VENOUS DRAINAGE OF THYROID GLAND:

- **Superior Thyroid Vein** -----> Internal Jugular
- **Middle Thyroid Vein** -----> Internal Jugular
- **Inferior Thyroid Vein** -----> Right and left brachiocephalic veins

PARATHYROIDS:

- They receive blood from the **inferior thyroid arteries**
- You can't live without them. Removing them can lead to inadequate blood calcium -----> **Tetany** -----> death. Give artificial calcium and PTH as therapy if they are removed.
 - Adults can live without the Thyroid gland itself. Children can't -----> Development disorders and retardation.

THE EAR

EXTERNAL EAR: Consisting of the ear canal and Tympanic Membrane

- External Features: **Helix, Antihelix, Tragus, Antitragus, lobule, Concha, Incisure, Triangular Fossa**
- **BLOOD SUPPLY TO EXTERNAL EAR**
 - External Carotid -----> **Posterior Auricular**
 - External Carotid -----> **Superficial Temporal**

- **EAR CANAL:**
 - Outer Ear Canal contains Ceruminous (wax) glands and hair
 - Inner ear canal is covered with skin
- **TYMPANIC MEMBRANE:** Cone-shaped, the size of a dime. It received the mechanical sound waves and transmits them to the middle ear.
 - The Tympanic Membrane is very thin, composed of three cellular layers:
 - Squamous Epithelium on the outer (lateral) surface
 - Fibrous layer, mostly consisting of **pars tensa**. In about 15% of the membrane surface area this layer is missing, yielding **pars flaccida**.
 - Inner mucous membrane

EXTERNAL ACOUSTIC MEATUS: The Tympanic component of the mastoid bone is immediately posterior to the *condyle of the mandible* (i.e. the TMJ joint). So watch it with jaw dislocations.

MIDDLE EAR: Consisting of the Eustachian Tube, Middle Ear Ossicles, and Middle Ear Muscles

- It can be divided into three regions:
 - **Epitympanum** -- above the rim of the tympanic membrane.
 - It contains the main parts of the malleus and incus.
 - **Mesotympanum** -- just medial (deep) to tympanic membrane
 - It contains the main part of the stapes.
 - **Hypotympanum** -- Below tympanic membrane
 - It contains carotid artery and jugular bulb
- **EUSTACHIAN TUBE:** It should be considered the *only opening* of the middle ear. It equilibrates pressure between middle ear and atmosphere.
 - Pressure is equilibrated *only when swallowing*, by the action of salpingopharyngeus and tensor palatini
 - CLINICAL -- don't give an infant a bottle when the infant is lying down. This can cause leakage into the Eustachian tubes -----> Middle Ear Infection (**Otitis Media**)
- Borders:
 - Medial (deep) Limit of Middle Ear:
 - **Promontory** of the cochlea (the first turn)
 - **Vestibular (Oval) Window** -- will move fluid as a result of vibrations of the stapes.
 - **Cochlear (Round) Window** -- relieves pressure from the vestibular window.
 - Lateral (Superficial) Limit of Middle Ear: **Tympanic Membrane**, or eardrum.
- Middle Ear Ossicles: Their purpose is to *transmit the mechanical sound wave from air to fluid*.
 - **Malleus** *attaches to the tympanic membrane*
 - The **Tensor Tympani Muscle** attaches to the neck
 - It is housed within the epitympanic recess
 - The **Chorda Tympani** *passes just medial to the malleus and superior to the tensor tympani*.
 - **Incus** Articulates with the head of the Stapes
 - It is housed within the epitympanic recess.
 - **Stapes**
 - The **Stapedius Muscle** attaches to its neck
 - It is housed within the mesotympanic space.
- BLOOD SUPPLY to Middle Ear: Lots of arteries, primarily from External Carotid but also from Internal
 - Stylomastoid A.
 - Inferior and Anterior Tympanic Aa.
 - Petrosal A.
 - Caroticotympanic A. (from internal)

TRANSMISSION OF SOUND WAVE: Ear Canal -----> Eardrum (Tympanic Membrane) -----> Malleus -----> Incus -----> Stapes -----> Promontory -----> Cochlea -----> Organ of Corti

MASTOID AIR CELLS: Linked to the middle ear by the **Antrum** of the middle ear.

- These air cells primarily lie in the squamosal and petrous portions of the temporalis bone, those portions overlying the middle ear.

- There is a correlation between middle ear infections and aeration of the mastoid air cells. *The more sclerotic (non-aerated) the mastoid cells, the higher the incidence of infection.*

INNER EAR: The Cochlea and Semicircular Canals. The Inner Ear is in the deepest part of the Temporal Bone -- the Petrous Part.

- **Cochlea:** Final receptor of sound-information, containing the **Organ of Corti** in the **Cochlear Duct**.
- **Vestibule:** Common chamber which contains:
 - **Utricle** -- static balance
 - **Saccul** -- static balance
- **Semicircular Canals:** Three semicircular canals in the three dimensions of space, for dynamic balance and detection of *angular velocity*.
 - **Endolymph Fluid** moves in order to detect angular velocity.
- **Osseus Labyrinth:** The outermost encasement of the Cochlea.
- **Membranous Labyrinth:** A labyrinth within the osseus labyrinth. A tube within a tube.
 - **Perilymph Fluid:** Flows on the outside of the membranous labyrinth. Endolymph fluid flows on the inside.

OTOLOGICAL PATHOLOGIES: Generally, infection tends to creep into the *supratympanic* (upper) region of the middle ear.

- **Eustachian Tube Dysfunction:**
 - Common in children, due to shorter, straighter tube.
 - Insert a **PE-Tube** into the tympanic membrane to equilibrate pressure. The tube is placed in lower part of eardrum.
- **Cholesteatoma:** Like a benign tumor, squamous epithelium from the eardrum builds up in the pars flaccida and invades the middle ear. It must be removed.
- **Otosclerosis:** A bone metabolism disorder that leads to conductive hearing loss via stapes fixation (i.e. stapes doesn't vibrate correctly).
 - Treatment: It can be treated surgically with implantation of a prosthetic stapes bone.
- **Acoustic Neuroma:** A tumor in the Vestibulocochlear (VIII) Nerve. It can impinge upon Facial (VII) at the same time, at the internal auditory meatus.

LYMPHATICS

Waldeyer's Rim: See Pharynx

SUPERFICIAL LYMPH NODES: All of these eventually drain into the Deep Cervical Lymph Nodes.

- They include the following:
 - **Occipital**
 - **Postauricular (Mastoid, Retroauricular)**
 - **Preauricular (Superficial Parotid)**
 - **Submandibular**
 - **Submental**
- Below the head and neck junction: **Superficial Cervical** and **Supraclavicular Nodes**
- DEEP CERVICAL LYMPH NODES: External to the carotid sheath.
- All of them ultimately drain into **Right Lymph Duct** on right side and into **Thoracic Duct** on left side.
- SUPERIOR GROUP
 - **Jugulo-Digastric**
 - **Jugulo-Omohyoid**
- INFERIOR GROUP
- TONGUE:
 - Anterior 2/3 -----> **Submandibular and Sublingual Nodes** -----> Jugulo-Omohyoid Nodes ultimately
 - Posterior 1/3 -----> *Directly into Superior Deep Cervical Nodes*
- THYROID GLAND, TONGUE: These two organs drain into the opposite side of the head and neck, somewhat. All other organs drain into the same side.